UDC 616.14-005(075.8)

Chronic venous insufficiency symptoms and complications, deep vein thrombosis in saphenofemoral junction

T.A. Shamsaddinskaya, N.M. Shamsadinskaya, S.S.Jafarova
Shams clinic, Azerbaijan Medical University, Baku

Summary: Purpose of research - protocol of treatment deep venous thrombosis during pregnancy after this complication complications, deep vein thrombosis. Research objectives -efficiency of various groups of drugs during pregnancy and different types of phlebotomy and using phlebotropic, anticoagulants, antiplatelet and anti-inflammantory pills. We used different groups of drugs. Using specific medication schedule, which changes in the period of 10 days, 2 months, 6 months, 1 year, measured by using duplex and doppler. To avoid complications like stomach ache and bleeding and have option to use several types of molecules and exclude different types of monotherapy, used multimorbidity and polypharmacy was used this new protocol of treatment. This tactic and protocol of treatment after thrombosis give recanalization by 80% in period by one year. Protocol of treatment was successful in this group of women and we recommended it hardly. After treatment all 58 patients give a birth to a child, for control all pregnancy period and after they take treatment by previously described periods and ones a time every year in five years. No one case of repeated thrombosis and formation of trophic ulcers in all patient. This protocol of cure used many types of molecule, which is difficult to use in same time, this method has advantages in treatment, take modern medicines taking into account comimorbidity.

Key words: Chronic venous insufficiency, complications, deep vein thrombosis, treatment protocol

Varicose vein due to obstruction of the deep vein system, occur throughout all period of pregnancy, complicated by chronic venous insufficiency, has symptomatic complications like cutaneous, hemorrhagic or thrombotic. Venous edema include class 3 (CEAP-classification), impression of swelling, fatigability, heaviness, pain, pruritus, most specific components of this disease. In anamnesis was symptoms like cramps, restless legs for years in previous disease. Pregnancy can increase rise of high venous pressure in the abdominal area, especially in vena cava inferior, which provide slow blood flowing and increased blood clotting. Risk factors of thrombosis at that types of changes are very high. Thrombosis during pregnancy is difficult to treat without fetal problems, so cure was during previous pregnancy history and monitoring in all period of pregnancy using the new medical scheldule. Here is new protocol of cure which include different types of molecules.

Materials and methods in period 2020-2025 include 58 patient in middle age 35-45 years with saphenofemoral thrombosis during pregnancy, cure in second trimesters and next periods, using different types of medicines in new protocol with treatment and evaluation symptoms and quantification.

Purpose of research - protocol of treatment deep venous thrombosis during pregnancy after this complication. Research objectives - efficiency of various groups of drugs during pregnancy and

different types of phlebotomy and using phlebotropic, anticoagulants, antiplatelet and anti-inflammantory pills. We used different groups of drugs. Using specific medication schedule, which changes in the period of 10 days, 2 months, 6 months, 1 year, measured by using duplex and doppler. To avoid complications like stomach ache and bleeding and have option to use several types of molecules and exclude different types of monotherapy, used multimorbidity and polypharmacy was used this new protocol of treatment.

For example her is information about two patient. Ceferova Shefeg 2001, patient 2 - Musayeva Vahida 1989. Diagnosis was sapheno-femoral deep venous thrombosis occlusive left limb Shefeg and right Vahida, clinical presentation after 10 days of cure, was measure by duplex ultrasound to find deep vein thrombosis so 10% of sapheno- femoral junction which was occlusive thrombosis and still remain high risk of pulmonary embolism and recommended bed rest and low activity either.

At first period which insist 10 days, patient take phlebotonics 1000 mg every day at 14 am , next one anticoagulant edoxaban 30mg every day 5 days at 10 a.m.; antiplatelet 75.mg two times in week wednesday (3) and saturday (7). Anti-inflammantory meloxicam in 15 mg dose every day 5 days, after only Monday (1) and Friday (5), so twice a week.

Duplex scan measurements and ultrasound surveillance was provided in several position.

Each participant took a rest in supine position to measure blood velocity. Ankle pump movement to research blood velocity with 1 min, 20 min lying in the same position until was measured. At the same time answered on questions from Civig Quality of life definition. Diagnostic and therapeutic management consequently varies by period 10 days, two month, six month and one year. Visible edema was examined from tendon thickening (Achilles) and ankle, measured by tape, in the same periods already described. To make detection of all changes they were recorded in medical history. Next was checking along the entire length saphenofemoral vein up to saphenofemoral junction. Reflux was investigated in junction and using duplex scan. Sapheno-popliteal junction DVT is described as proximal when it encompasses at least part of popliteal vein, so below the popliteal vein is described as distal, whether it affects the venous axes fibular and posterior tibial veins, muscle veins gastrocnemius or soleus. In table 2 we describe periods of research and recanalization percentages for all patients from study.

Molecule	Dose	Using by days
Phlebotropic	1000 mg	10 days every day 2,4,6 in week, 14 a.m.
Anticoagulants (edoxaban)	30 mg	Each day 10 days, after 1,5 days, so two times in week, 10.00 a.m.
Antiplatelet (clopidogrel)	75 mg	3,7 days of week at 10.00 am.
Anti-inflammantory 1(meloxicam) 2(ketorolac injection)	15 mg 1.0 intramuscularly	5 days, every day, after 3, 7, twice week, at 21.00 p.m. 5 days every day, after 1,5 days For 5 more, total 10 injection

Table 1. Our protocol of treatment chronic venous insufficiency symptoms and complications, deep vein thrombosis in saphenofemoral junction

Characteristic	Value	Numerous
10 days	10%	58
2 months	30-50%	46: 12
6 months	60-70%	37: 21
1 year	80-90%	58

Phlebotropic and edema protective drugs, nonsteroidal inflammantory drugs, mobilization is essential, cure reduce risk of thrombus extension and deep venous thrombosis factors. To proposed risk of bleeding we did analysis. Size of vessel and correlation between variable outcomes allowing us to definite conclusions. Worsening symptoms suggesting create thrombotic burden, ultrasonographic variables which was presented in percentages using rarely ,or early outcomes. The ultrasound surveillance allowing monitor find effect of reduced regiments of anticoagulants, antiplatelet, nonsteroidal anti -inflammantory drugs. To decreasing venous stasis and ulcer we used graduated compression stoking class 1. Compression was widely used after giving a birth to a child and during pregnancy to prevent deep venous thrombosis again. Important consideration was control d-dimer, coagulogram, inflammantory panel every period with was previously described. This intervention methods used to control recanalization by duplex scan and doppler, prevent lymphedema and peripheral venous disease with ulcer.

Hemodynamic component is important, but most frequently secondary, since engendered by initial disease of vein wall. Preoperative duplex ultrasound has resolved this difficulties. To research we use blood test like extended coagulogram, d-dimer, general blood test, c-reactive protein to find changes in blood parameters.

Treatment of thrombotic complication compression therapy include. Active and passive compression therapy was useful after surgery stripping, phlebectomy, surgery of perforating vein and tributary varicose veins. In ordinary situations in patients C1,2 grade CEAP-classification, use compression is very difficult to accept, so quality of explanation very important. Checking swelling of legs use measuring tape or legometr, show a difference before and after using treatment, so results improved in all stages of chronic venous disorders.

In picture 1, presented by case left extremities acute thrombosis, measurement was done by duplex ultrasound which help to see thrombotic mass, sizes, lenght and width of thrombosis. That case of disease exclude flotation of the thrombotic mass. The patient named Mageramova Leyla, first time appeared to hospital with complain of pain, swelling leg and skin changes C4 grade. Measurements and analysis which was done in same moment hospital admission after 12 day from first symptoms this pathology. First result was measure after 10 days of cure and show recanalization near 10%, next one after 2 month 50%, after 6 month - 70%, in 1 year - 90% of recover. So complete occlusion of superficial vein by thrombus, which can provide deep venous thrombosis and pulmonary embolism was reduced in 1 year and presence tropic changes, skin definition.

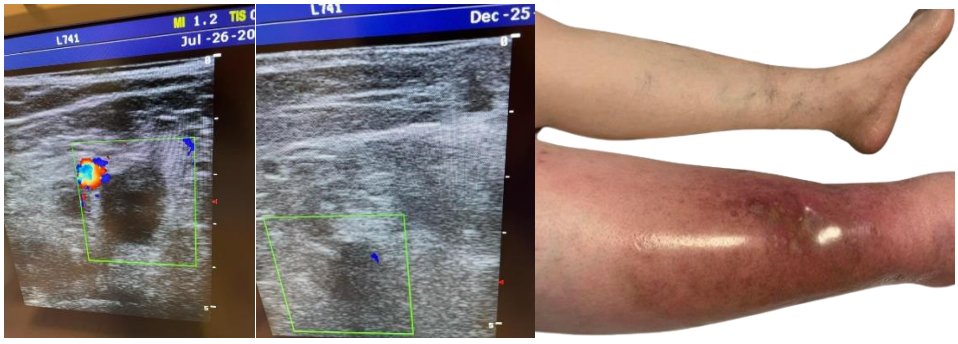

Figure1. Saphena-femoral occlusive thrombosis and cutaneous disorders. C4 grade

The first results of recanalization and forming tributary veins in 10 days after treatment deep sapheno-femoral vein with thrombosis and complication CVI. Using CEAP classification grade C3, without thrombosis but with pain and difficulties in her life, Quality of life were measured by using

CIVIG questionnaire. First of all we used phlebotonic, venotonic, vasoprotectiv, antiinflammantory nonsteroidal drugs, local treatment with gels too, compression stoking class 1 (18-23 mm H). Because this groups of complication cannot use class 2, which they need. We can afford it because patient has examination in a supine position in first 10 days and most of all, limited physical activities, so pressure of stockings was class 1. The first case is measurement of sapheno-popliteal junction to find venous disorders and disease of venous system. The second one review and analyze and available complex treatment venous deep sapheno-femoral thrombosis period of measurements and regarding the therapeutic approach in 10 days, 2 month, 6 month and 1 year using permanent treatment, by using different groups of drugs. Difficult to correctly classify the results, we used diameter of junction in millimeters and using square of junction, affected area and percentages of recanalization. Blood flow volume with velocity was measured by program and we used experimental protocol in venous conclusion.

Lower extremity after two month of therapy sapheno-femoral junction show recanalization 40%, which showed in picture 2.

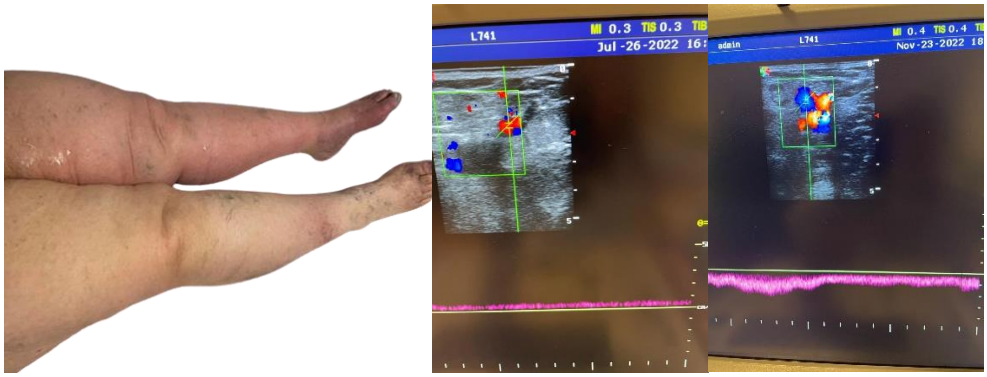

Figure 2. Duplex doppler measurement with recanalization 40% and recanalization (left extremities) in 80%

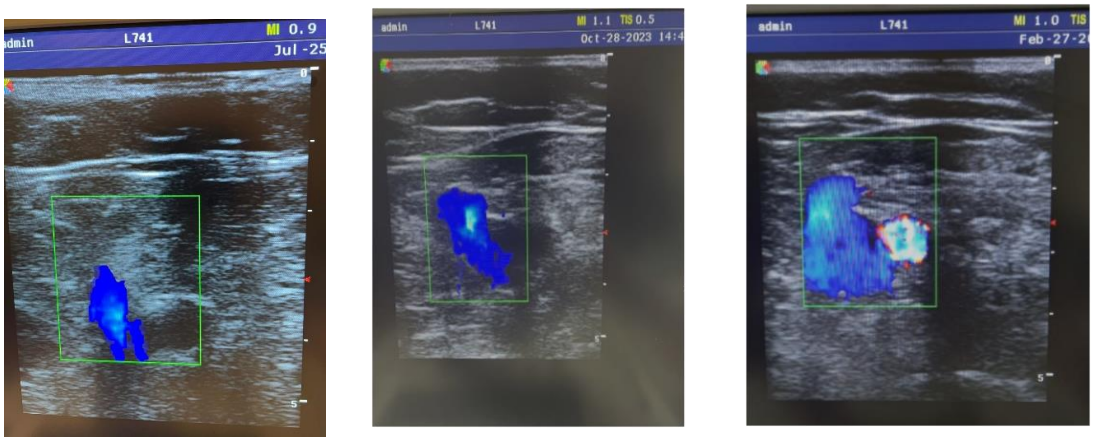

Figure3. Vascular investigations in venous disease by ultrasound techniques.

The calculation in all 58 patients with thrombosis was using next steps:

1. Perceived vessel as an ellipse
2. Measured the area of the vessel counted as 100%

3. Divided into part of an ellipse
4. Considered damaged part in percentages, based on calculating size thrombosis and mass
5. Revascularization from 10% till 90%

Medical treatment after different complication with deep and superficial thrombosis, using different groups of venoactive drugs and this protocol by using pills only 3 times in week, same time this therapy improve effectiveness of cure and no one case from 58 patients with bleeding, or complication associated with taking medications. This opportunity help women give a birth to a children, so that tactic give possibility to use all types of modern medications to create better results in that difficult conditions, give a chance to get pregnant again and we already have that type of patient.

Treatment period 6 month and year the following outcomes were achieved (Figure 3).

This patient get more than 90% of recanalization after deep venous thrombosis sapheno-femoral juncsion, increase better blood flow, optimize chronic venous disorders and congenital venous changes without any surgical manipulations and cost save therapy without hospitalization for long period and maintain quality of life during treatment.

Conclusion. This tactic and protocol of treatment after thrombosis give recanalization by 80% in period by one year. Protocol of treatment was successful in this group of women and we recommended it hardly. After treatment all 58 patients give a birth to a child, for control all pregnancy period and after they take treatment by previously described periods and ones a time every year in five years. No one case of repeated thrombosis and formation of trophic ulcers in all patient. This protocol of cure used many types of molecule, which is difficult to use in same time, this method has advantages in treatment, take modern medicines taking into account comimorbidity.

REFERENCES

1. Cacione D.G., Novaes G.D., Silva J.C. Correlation between presence of lower limb varicose veins and deep venous thrombosis // J Vasc Bras., 2020, 19, e20200081.
2. Chang S.L., Huang Y.L., Lee M.C. et al Association of Varicose Veins With Incident Venous Thromboembolism and Peripheral Artery Disease // JAMA, 2018, 319, p. 807-17.
3. Chopard P., Spirk D., Bounameaux H. Identifying acutely ill medical patients requiring thromboprophylaxis // J. Thromb Haemost., 2006, 4, p.915-916.
4. Kemp M.T., Obi A.T., Henke P.K. et al. A narrative review on the epidemiology, prevention, and treatment of venous thromboembolic events in the context of chronic venous disease // J Vasc Surg Venous Lymphat Disord., 2021, 9, p.1557-67.
5. Konstanttinides S.V., Meyer G., Becattini C. et al. ESC Scientific Document Group. 2019 ESC Guidelines for the diagnosis and management of acute pulmonary embolism developed in collaboration with European Respiratory Society (ERS) // Eur Heart J., 2020, 41, p.543-603.
6. Merriman E., Chunilal S., McRae S. et al. Two weeks of low molecular weight heparin for isolated symptomatic distal vein thrombosis (Twister study); final analysis of 242 patients (abstract) // Res Pract Thromb Haemost., 2020, 4
7. Nicolaides A., Kakkos S., Baekgaard N. et al. Management of chronic venous disorders of the lower limbs // Guidelines According to Scientific Evidence, Part II. Int Angiol., 2020, 39, p.175-240.
8. Pang C., Lim C.S.. Brookes J. Emergening impotance of molecular pathogenesis of vascular malformation in clinical practice and classifications // Vas med., 2020, 25, p.364-77.
9. Righini M., Paris S., Le Gal G. et al. Clinical relevance of distal deep vein thrombosis-Review of literature data // Thromb Haemost., 2006, 95, p.56-64.
10. Ramelet AA. Exercise include vasculitis // JEADV, 2006, 20, p.423-427.

Xroniki venoz çatışmazlığı simptomları və ağırlaşmaları, saphenofemoralda dərin venoz trombozu

T.A. Şəmsədinskaya, N.M. Şəmsədinskaya, S.S. Cəfərova
Şəms Klinikası, Azərbaycan Tibb Universiteti, Bakı

Xülasə: Tədqiqatın məqsədi bu ağırlaşmadan sonra hamiləlik zamanı dərin ven trombozunun müalicəsi üçün protokoldur. Tədqiqatın məqsədləri hamiləlik dövründə müxtəlif dərman qruplarının effektivliyi və müxtəlif növ flebotomiya və phlebotropic, anticoagulant, antiplatelet və antiinflamatuar tabletlərin istifadəsidir. Müxtəlif qrup dərmanlardan istifadə etdik. 10 gün, 2 ay, 6 ay, 1 il ərzində dəyişən xüsusi dərman cədvəlindən istifadə edərək, dupleks və doppler istifadə edərək ölçülür. Qarın ağrısı və qanaxma kimi fəsadların qarşısını almaq və bir çox növ molekullardan istifadə etmək və müxtəlif monoterapiya növlərini aradan qaldırmaq, multimorbidlik və polifarmasiyanı aradan qaldırmaq üçün bu yeni müalicə protokolundan istifadə edilmişdir. Trombozdan sonra bu taktika və müalicə protokolu bir ilə qədər 80% rekanalizasiyanı təmin edir. Müalicə protokolu bu qrup qadınlarda uğurlu oldu və biz bunu şiddətlə tövsiyə etdik. Müalicədən sonra 58 xəstənin hamısı uşaq dünyaya gətirir, hamiləliyin bütün dövrünə nəzarət edir və bundan sonra onlar əvvəllər qeyd olunan dövrlər üzrə və beş il ərzində ildə bir dəfə müalicə alırlar. Bütün xəstələrdə təkrar tromboz və ya trofik xoraların əmələ gəlməsi ilə bağlı heç bir hadisə olmamışdır. Bu müalicə protokolunda eyni zamanda istifadəsi çətin olan bir çox növ molekullardan istifadə olunur, bu üsul müalicədə üstünlüklərə malikdir, müasir dərmanlar əlavə xəstəliklər nəzərə alınmaqla aparılır.

Açar sözlər: xroniki venoz çatışmazlıq, ağırlaşmalar, dərin vena trombozu, müalicə protokolu

Симптомы и осложнения хронической венозной недостаточности, тромбоз глубоких вен в сафенофеморальном соустье

Т.А. Шамсадинская, Н.М. Шамсадинская, С.С. Джафарова
Клиника Шамса, Азербайджанский медицинский университет, Баку

Резюме: Цель исследования - протокол лечения тромбоза глубоких вен во время беременности после этого осложнения хронической венозной недостаточности. Задачи исследования - эффективность различных групп препаратов во время беременности и различных видов флеботомии и использования флеботропных, антикоагулянтных, антиагрегантных и противовоспалительных таблеток. Мы использовали различные группы препаратов. Используя определенный график приема лекарств, который меняется в течение 10 дней, 2 месяцев, 6 месяцев, 1 года, измеряемый с помощью дуплекса и допплера. Чтобы избежать осложнений, таких как боли в животе и кровотечения, и иметь возможность использовать несколько типов молекул и исключить различные виды монотерапии, использовали мультиморбидность и полипрагмазию, был использован этот новый протокол лечения. Такая тактика и протокол лечения после тромбоза дают реканализацию на 80% в срок до одного года. Протокол лечения оказался успешным у этой группы женщин и мы настоятельно его рекомендовали. После лечения все 58 пациенток рожают ребенка, для контроля весь период беременности и после этого они принимают лечение по ранее описанным периодам и один раз в год в течение пяти лет. Ни одного случая повторного тромбоза и образования трофических язв у всех пациенток. В этом протоколе лечения использовано много типов молекул, которые

трудно использовать одновременно, этот метод имеет преимущества в лечении, принимать современные лекарства с учетом сопутствующей патологии.

Ключевые слова: хроническая венозная недостаточность, осложнения, тромбоз глубоких вен, протокол лечения

Daxil olub: 10.06.2023